

Treatment of Class III Relapse Due to Late Mandibular Growth Using Miniscrew Anchorage

YOON-AH KOOK, DDS, MSD, PHD
SEONG-HUN KIM, DMD, MSD

Skeletal Class III malocclusion can be treated in growing patients with either fixed or orthopedic appliances.¹⁻⁶ Premolar extractions are often required in adolescents with both anterior crossbite and crowding. During treatment, however, long-term wear of Class III intermaxillary elastics can result in flaring of the maxillary anterior teeth and lingual tipping of the mandibular incisors.⁷ Continued mandibular growth may lead to relapse, even when patient compliance is adequate.⁸⁻¹⁰

The effects of excessive mandibular growth after treatment can be treated in two ways: with a fixed appliance, which generally worsens tipping and flaring, or with surgery.¹¹⁻¹³ If the mandibular first premolars have already been extracted, surgery will involve decompensation to regain mandibular space, followed by prosthetic treatment. When all four premolars have been extracted, the mandibular first premolar space must be regained through presurgical orthodontics for placement of an implant or a bridge. Meanwhile, correction of maxillary incisor flaring will require additional extractions, Le Fort I surgery, or distalization of the maxillary posterior teeth.¹⁴ Further extraction will compromise the functional and esthetic results; Le Fort I surgery is overly invasive. Therefore, distalization of the posterior teeth is often the best option. Although such treatment is difficult, it can now be facilitated by miniscrew anchorage.

Miniscrew Anchorage Technique

In the new approach presented here, an anterior subapical osteotomy (ASO) is performed to correct maxillary anterior flaring after sufficient space has been opened with maxillary molar dis-

talization.¹⁵⁻¹⁷ This procedure is not only less risky and costly than Le Fort I surgery, but allows efficient upper-lip movement.¹⁸⁻²⁰ At the same time, a mandibular bisagittal split ramus osteotomy (BSSRO) is performed to correct mandibular excess (Fig. 1).

Direct retraction of the molars is possible without miniscrew anchorage, but would require multiple transpalatal arches (TPAs) in a complex design. A single miniscrew, placed palatally under local anesthesia, can provide sufficient skeletal anchorage for maxillary molar distalization (Fig. 2). A TPA is bonded to the head of the screw and to the lingual surfaces of the maxillary premolars with composite resin, after sandblasting the screw head and wire to facilitate mechanical retention. Open-coil springs are then inserted to distalize the second and then the first molars. During this process, it is sometimes helpful to place additional miniscrews to avoid extruding the maxillary molars and causing premature contact.

Case 1

A 19-year-old female presented with mandibular protrusion (Fig. 3). All four first premolars had been extracted during early adolescence, but continued mandibular growth had caused a relapse of the Class III malocclusion. The patient had a concave profile with an acute nasolabial angle and mild facial asymmetry (Table 1). The six anterior teeth had a Bolton discrepancy of 73% (2.7mm maxillary excess or 2.1mm mandibular deficiency). The patient had an edge-to-edge occlusion, and the chin was deviated 1mm to the left. The mandibular anterior teeth were in linguoversion, with a mild maxillary diastema. The left third

Dr. Kook is Associate Professor and Chairman, Department of Orthodontics, Catholic University of Korea, Kangnam St. Mary's Hospital, #505 Banpo-dong, Seocho-gu, Seoul, South Korea; e-mail: kook190036@yahoo.com. Dr. Kim is Assistant Professor, Department of Orthodontics, Catholic University of Korea, Uijongbu St. Mary's Hospital, Seoul, South Korea.



Dr. Kook



Dr. Kim

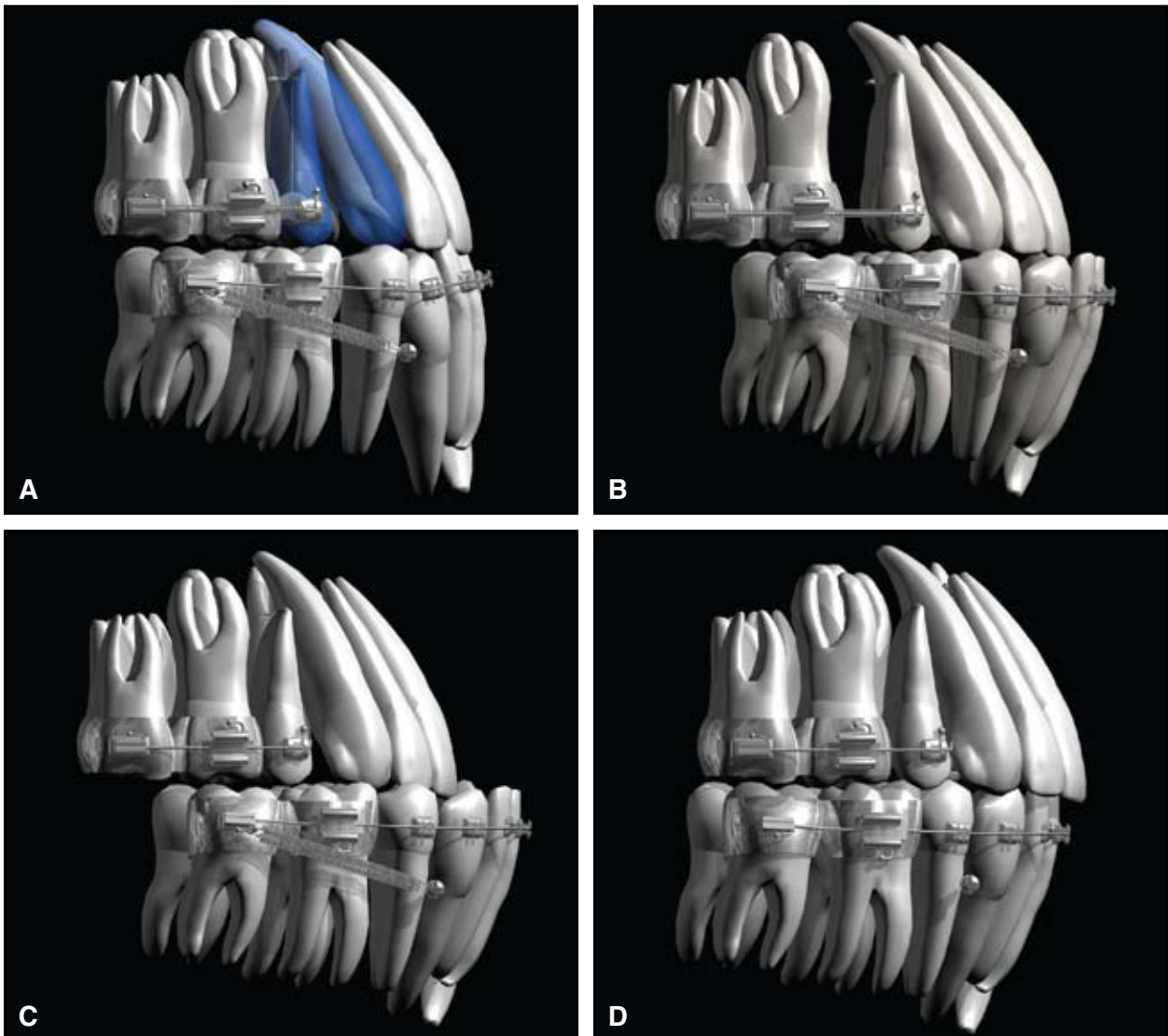


Fig. 1 Treatment of Class III relapse. **A.** Maxillary molar distalization and mandibular anterior decompensation using palatal miniscrew and mandibular buccal miniscrews. **B.** Before orthognathic surgery. **C.** After maxillary anterior subapical osteotomy (ASO). **D.** After mandibular bisagittal split ramus osteotomy (BSSRO).

Treatment of Class III Relapse Using Miniscrew Anchorage



Fig. 2 Dual-Top Anchor System miniscrew used for maxillary molar distalization.

molars were impacted in both arches.

Distalization of the maxillary molars was planned, followed by ASO. It was decided not to reopen the space in the mandibular arch during decompensation; rather, the arch was to be moved forward in preparation for BSSRO, which would achieve a skeletal Class I relationship with adequate overbite and overjet.

Preadjusted .022" brackets were bonded to the mandibular teeth and the maxillary molars, and an .016" nickel titanium archwire was inserted

for initial leveling. A JA-type, self-drilling Dual-Top Anchor System miniscrew* (1.6mm in diameter, 8mm long) was inserted palatally between the premolars, and an .036" TPA was bonded to the screw head and the lingual surfaces of the maxillary premolars (Fig. 4). The mandibular arch was moved forward by inserting a miniscrew between the canine and the second premolar on each side and attaching nickel titanium closed-coil springs**

*Registered trademark of JEIL Medical Corp., #702, Kolon Science Valley 2nd 822, Guro-Dong, Guro-Ku, Seoul, South Korea; www.jeilmed.co.kr.

**Jin Sung Industrial Co., Ltd., 137-1, Ojeon-dong, Uiwang-si, Gyeonggi-do 437-070, Seoul, South Korea; www.smawire.com.

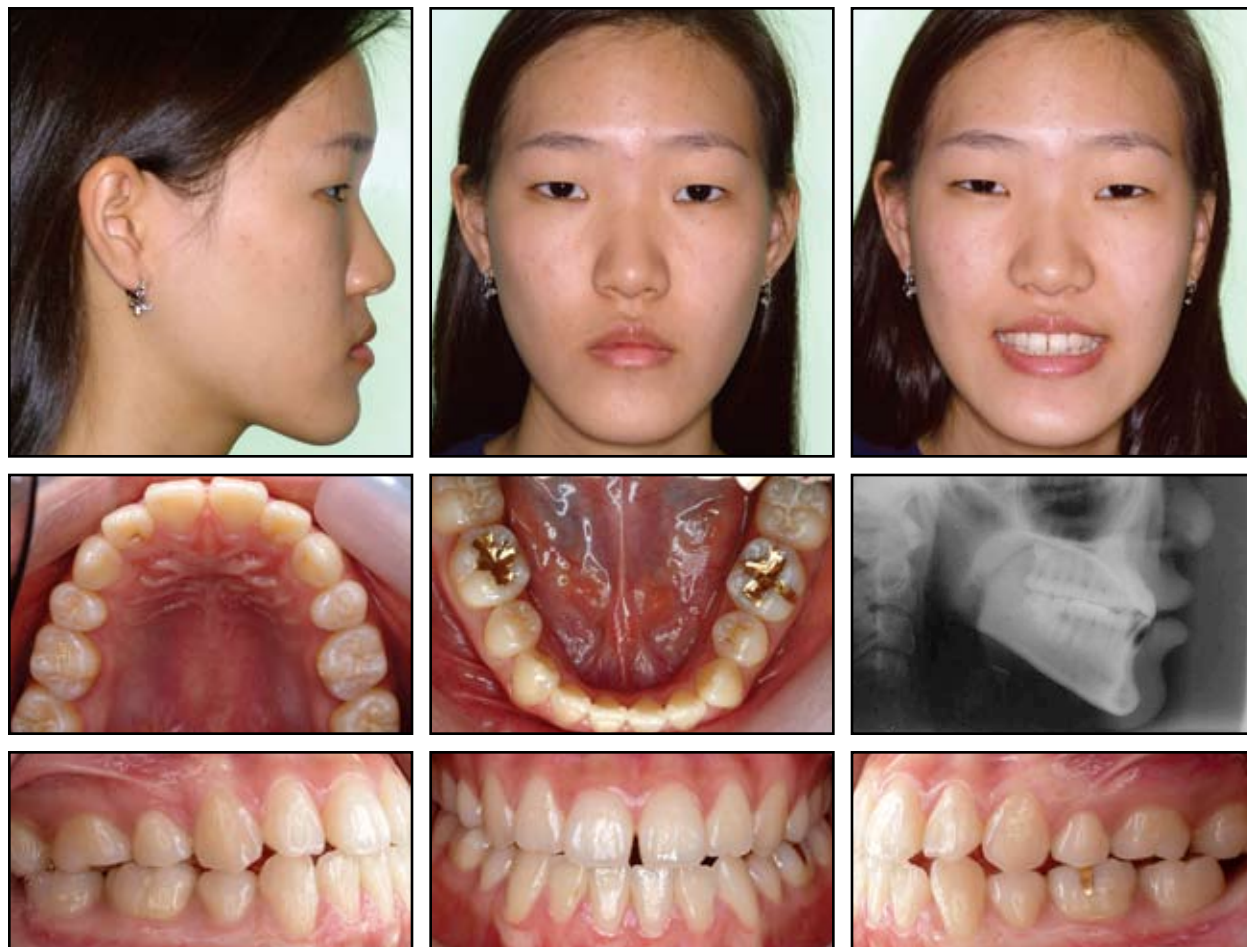

Fig. 3 Case 1. 19-year-old female patient with mandibular protrusion before treatment.

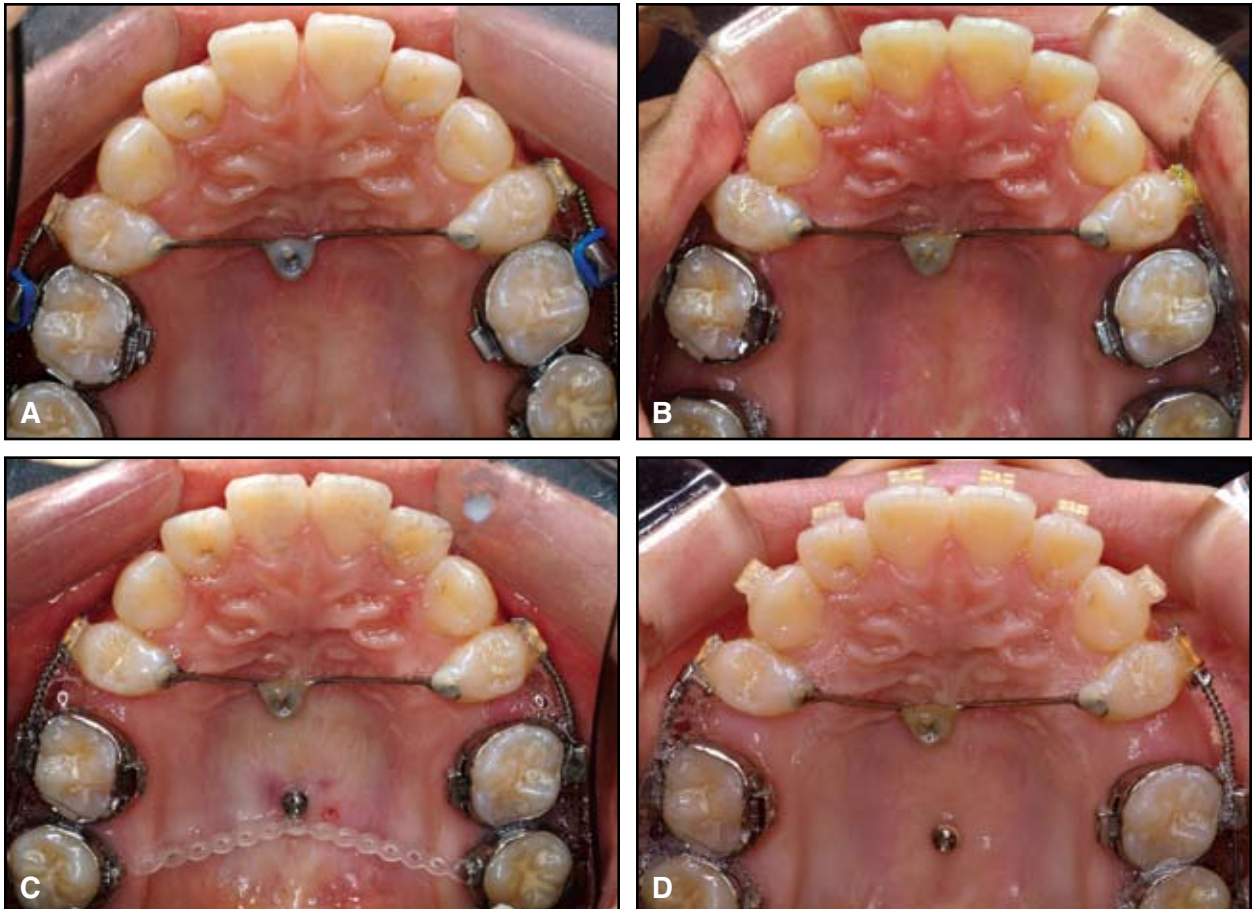

Fig. 4 Case 1. Maxillary molar distalization. A. Transpalatal arch (TPA) bonded to palatal miniscrew head and lingual surfaces of maxillary second premolars. B. Distalization of second molars. C. Distalization of first molars, with additional palatal miniscrew and buccal miniscrews used for second molar intrusion. D. After molar distalization.

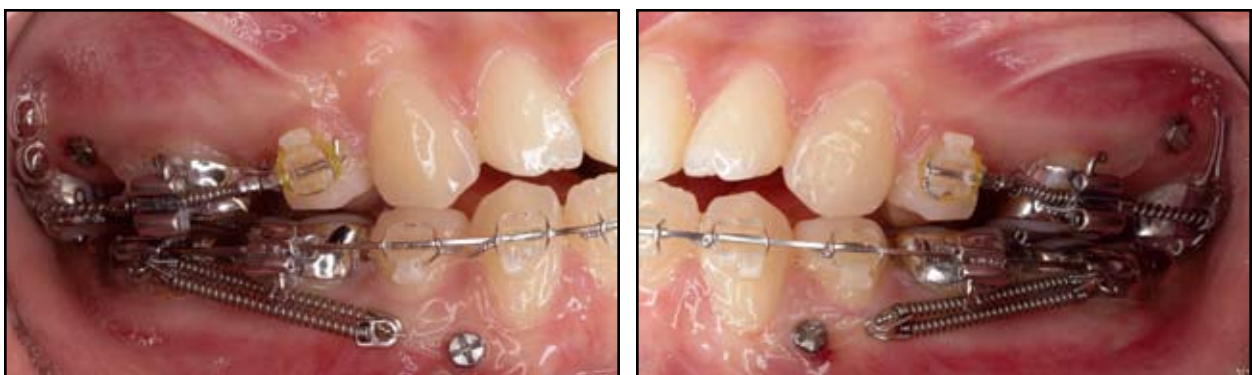


Fig. 5 Case 1. Miniscrews inserted between mandibular canines and second premolars, with nickel titanium closed-coil springs attached to second molars.

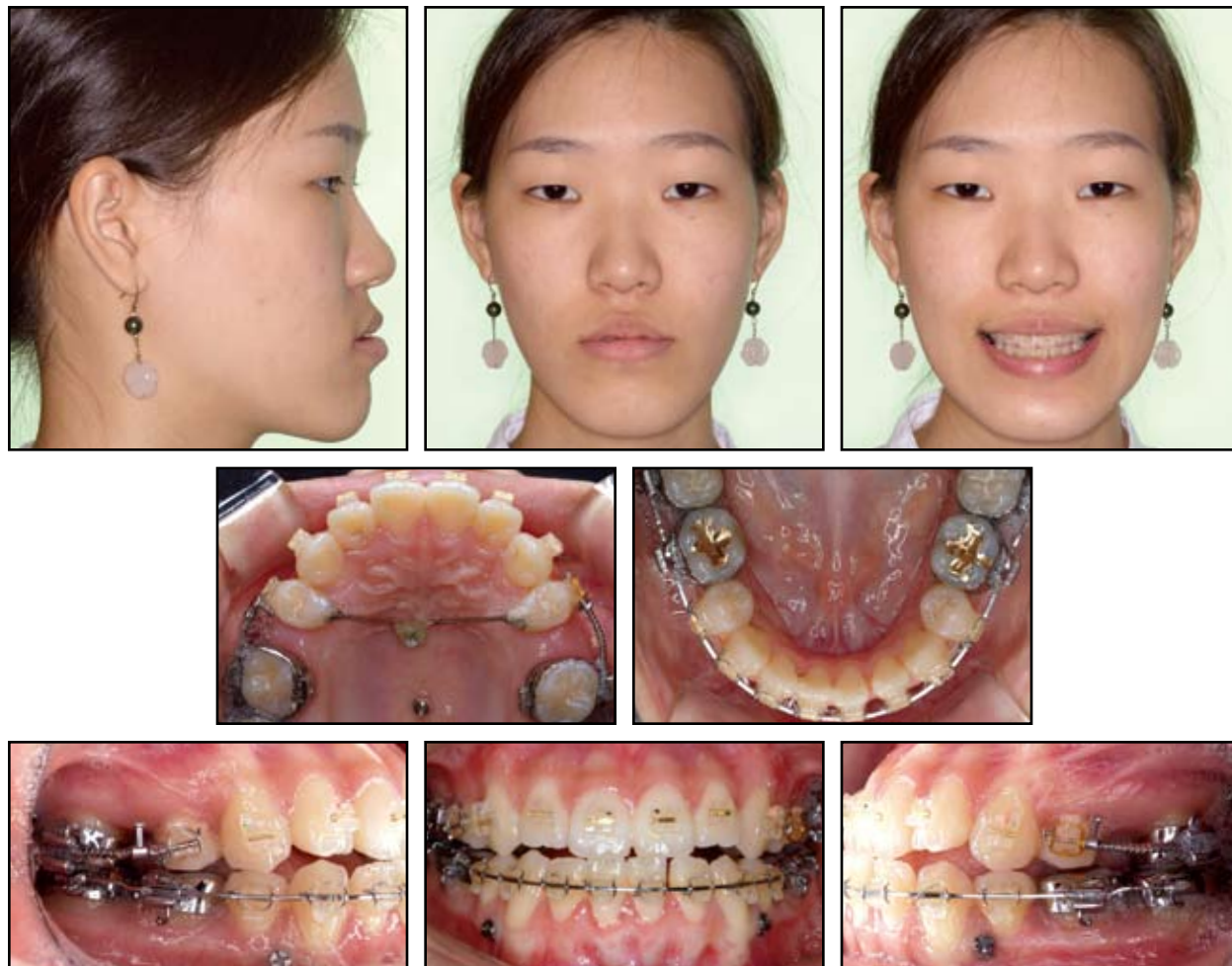

Fig. 6 Case 1. After seven months of distalization, showing increased mandibular protrusion due to decompensation.

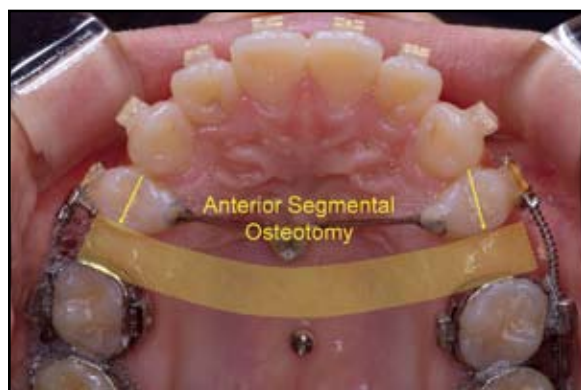

Fig. 7 Case 1. Regained space to be closed with ASO.

between the miniscrews and the second molars (Fig. 5).

After seven months of distalization, more than 5mm of space had been created between the maxillary first molars and second premolars. Mandibular protrusion was increased by the forward movement of the lower arch (Fig. 6), but the maxillary anterior teeth remained stationary because of the miniscrew anchorage (Fig. 7).

After nine months of treatment, the regained space was surgically closed with ASO, followed by BSSRO. The six maxillary anterior teeth were reproximated and finished. Total treatment time was 18 months.

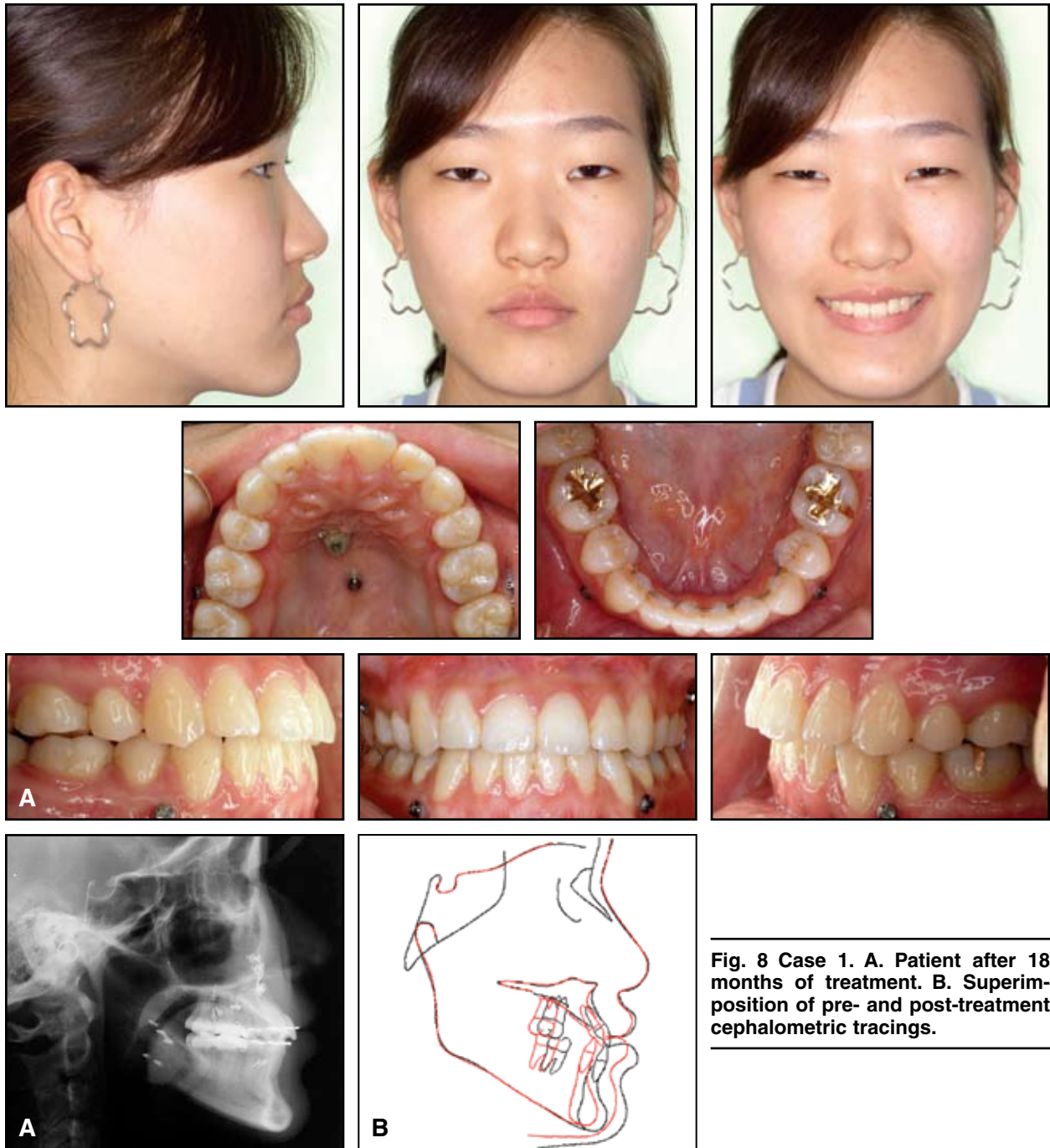


Fig. 8 Case 1. A. Patient after 18 months of treatment. **B.** Superimposition of pre- and post-treatment cephalometric tracings.

After debonding, a more balanced relationship between the upper and lower arches was evident, with significant improvement in the profile and jaw line, adequate overbite and overjet,

and Class I molar and canine relationships (Fig. 8). Follow-up records taken one year after surgery showed stable results (Fig. 9).

Treatment of Class III Relapse Using Miniscrew Anchorage

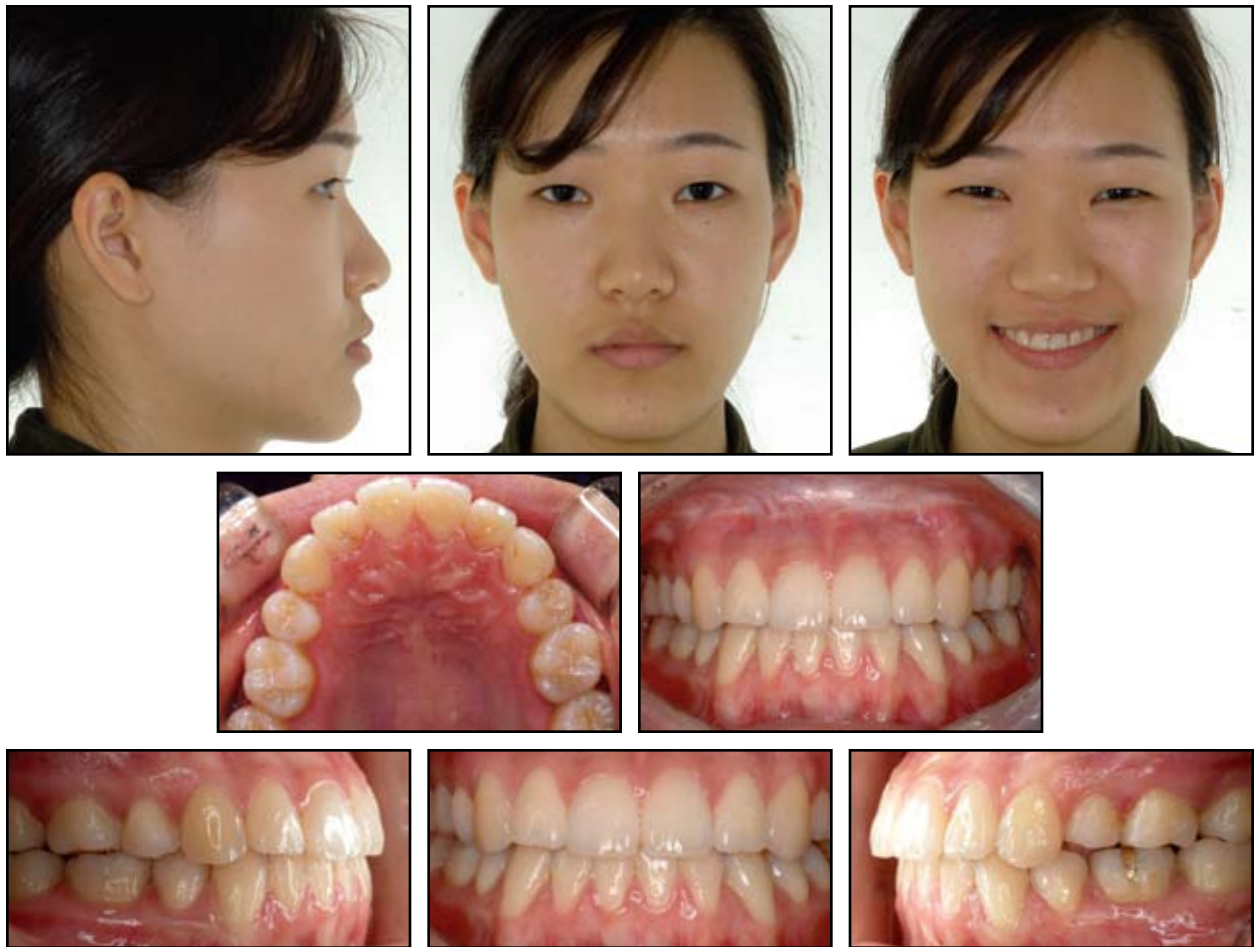

Fig. 9 Case 1. Follow-up records taken one year after surgery.

TABLE 1
CASE 1 CEPHALOMETRIC DATA

	Pretreatment	Presurgery	Post-Treatment
SNA	82.8°	83.0°	81.9°
SNB	84.6°	85.1°	82.5°
ANB	-1.9°	-2.1°	-0.6°
Occlusal plane angle	11.9°	10.6°	9.8°
Mandibular plane angle	30.5°	28.9°	27.2°
U1-NA	9.6mm	9.9mm	9.8mm
U1-NA	31.5°	30.5°	32.7°
L1-NB	5.0mm	8.8mm	3.7mm
L1-NB	20.2°	35.3°	19.4°
Interincisal angle	130.2°	116.4°	128.5°
U1-FH	119.5°	119.8°	120.8°
L1-GoMe	79.8°	95.0°	83.4°
Upper lip-E line	1.5mm	3.8mm	0.2mm
Lower lip-E line	-0.8mm	-1.0mm	-1.5mm

Case 2

A 16-year-old male presented with the chief complaint of crooked teeth. He had undergone orthodontic treatment with maxillary second premolar extractions to correct crowding during early adolescence. Clinical examination revealed a concave profile with a skeletal Class III malocclusion and an acute nasolabial angle (Fig. 10). The mandibular dental midline and the chin were deviated 2mm to the right. The patient had a Class I molar relationship and a Class III canine relationship, a 1mm overbite, and a mild negative overjet (Table 2). The six anterior teeth had a Bolton ratio of 75.6% (1.0mm maxillary excess or .8mm man-

dibular deficiency).

The treatment plan consisted of maxillary molar distalization using miniscrew anchorage, combined with a maxillary ASO and mandibular BSSRO. Genioplasty was also recommended to further improve the facial profile. The patient had a posterior discrepancy, and his third molars were developing normally, so the maxillary second molars were extracted. The mandibular third molars were also extracted to relieve mandibular crowding. A Dual-Top Anchor System miniscrew*

*Registered trademark of JEIL Medical Corp., #702, Kolon Science Valley 2nd 822, Guro-Dong, Guro-Ku, Seoul, South Korea; www.jeilmed.co.kr.

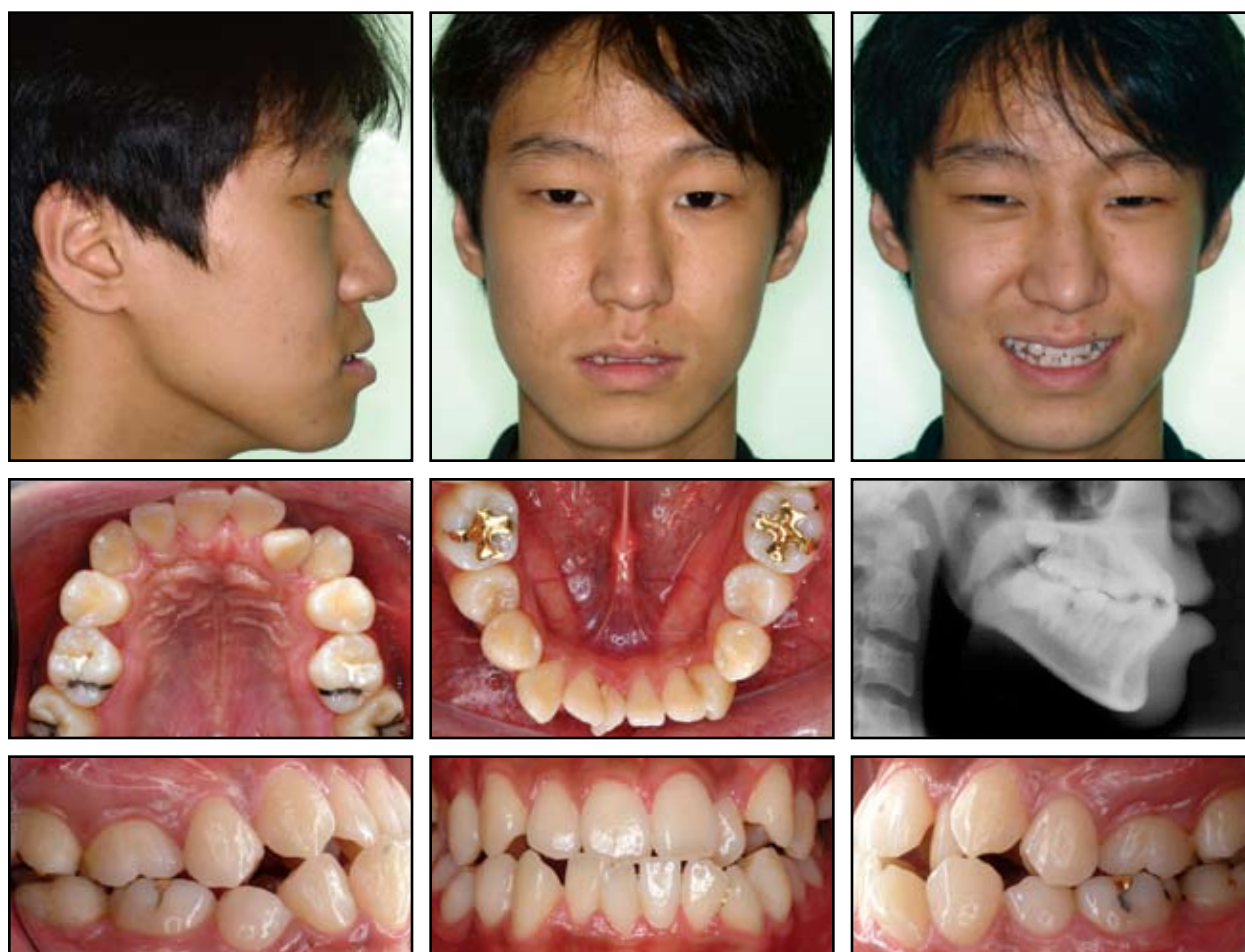

Fig. 10 Case 2. 16-year-old male patient with skeletal Class III malocclusion before treatment.

Treatment of Class III Relapse Using Miniscrew Anchorage

TABLE 2
CASE 2 CEPHALOMETRIC DATA

	Pretreatment	Presurgery	Post-Treatment
SNA	79.5°	81.3°	77.2°
SNB	80.1°	81.3°	75.1°
ANB	-0.7°	0.1°	2.1°
Occlusal plane angle	7.1°	8.0°	13.1°
Mandibular plane angle	30.0°	29.9°	28.4°
U1-NA	8.2mm	9.0mm	9.5mm
U1-NA	41.1°	42.4°	37.2°
L1-NB	8.2mm	11.2mm	9.5mm
L1-NB	28.5°	44.0°	35.5°
Interincisal angle	111.1°	93.6°	105.1°
U1-FH	129.8°	134.2°	125.0°
L1-GoMe	89.2°	102.4°	101.5°
Upper lip-E line	-2.3mm	-1.2mm	-3.2mm
Lower lip-E line	3.0mm	5.6mm	-1.2mm

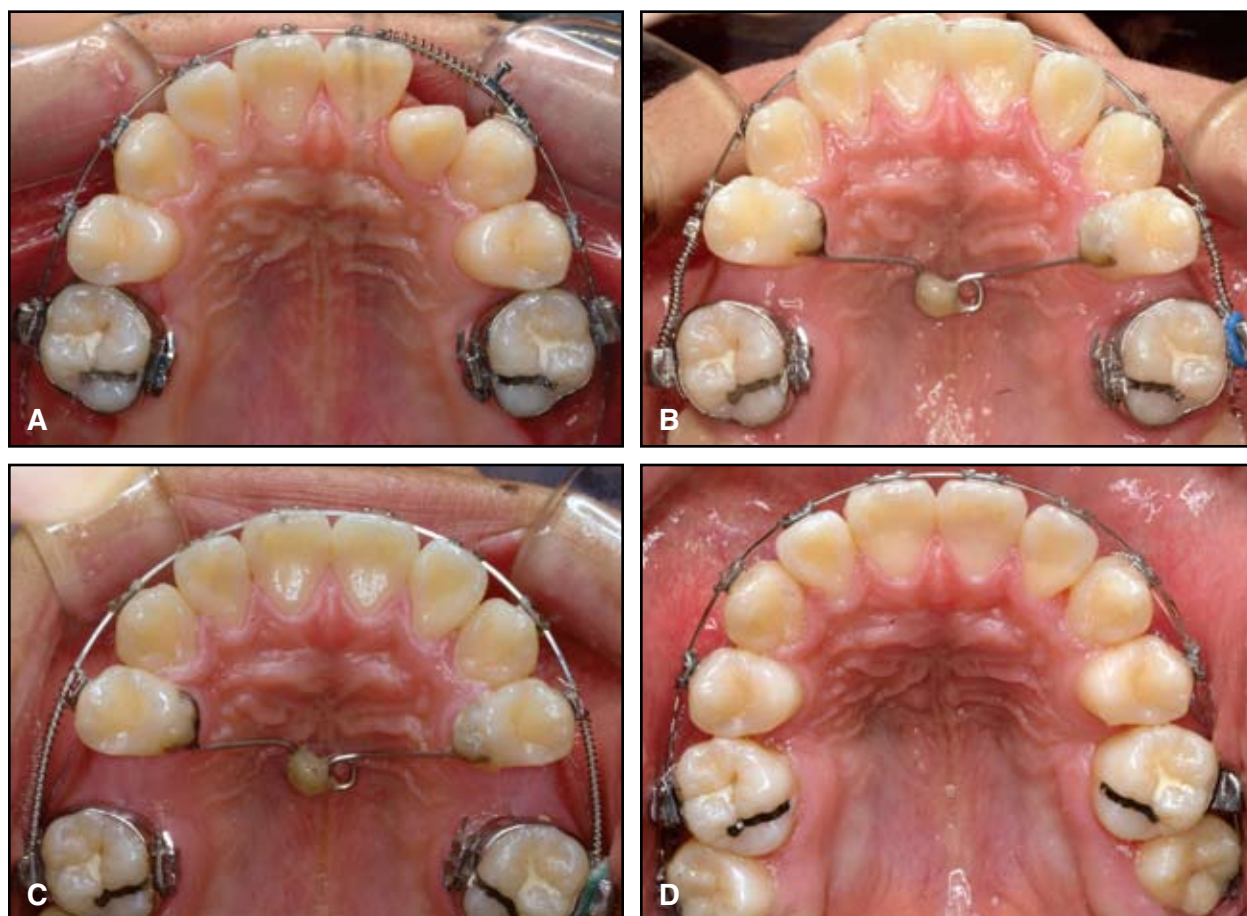

Fig. 11 Case 2. Treatment in maxillary arch. **A.** After extraction of maxillary second molars. **B.** TPA bonded to single palatal miniscrew and first premolars. Open-coil springs used to distalize first molars as third molars begin to erupt. **C.** After 6mm of molar distalization. **D.** Maxillary arch after ASO.

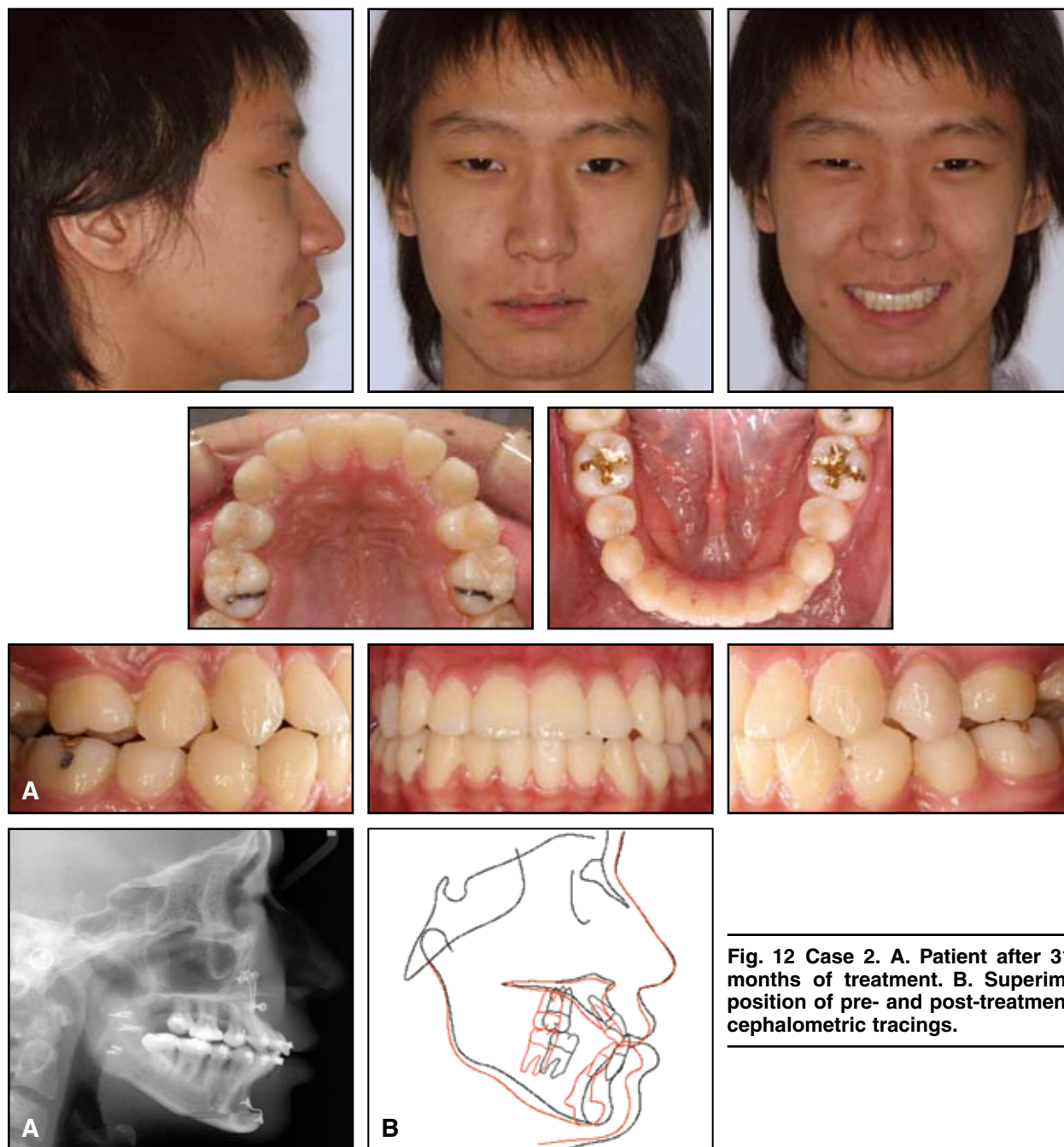


Fig. 12 Case 2. A. Patient after 31 months of treatment. **B.** Superimposition of pre- and post-treatment cephalometric tracings.

(1.6mm in diameter, 8mm long) was inserted in the midpalate, and a TPA was used to connect the miniscrew to the premolars, as in Case 1 (Fig. 11).

Distalization of the maxillary molars created a total of 6mm of space between the first molars and first premolars (Fig. 11C), and the ASO and BSSRO with advancement genioplasty were then

performed.

The total treatment time was 31 months, which was longer than expected because the patient missed several appointments. After debonding, the patient had adequate overjet, significantly improving the profile, with Class II molar and Class I canine relationships (Fig. 12).

Discussion

The midpalate's relatively thick cortical bone, thin mucosal tissue, and absence of roots and major nerves and vessels make it a good site for miniscrew placement.^{15-17,21,22} Traditionally, anchorage in this area has been achieved with large-diameter, osseointegrated dental implants.^{23,24} Because of their relatively long healing period, complicated installation and removal, and high cost, however, they are gradually being supplanted by miniscrews.^{25,26} The small, self-drilling miniscrews used in the cases described here are convenient and provide superior mechanical retention for skeletal anchorage.

In patients with skeletal Class III relapse due to continued mandibular growth after extraction treatment in the early permanent dentition, conventional surgical correction is difficult because of the tendency of the maxillary anterior teeth to flare, which limits the available amount of setback movement. Le Fort I surgery may result in posterior open bite and an unstable occlusal relationship. In addition, a long period of postoperative orthodontic treatment is required, and there is a risk of injury to vital structures, such as the greater palatal neurovascular bundle, during fracture and repositioning of the maxilla,²⁷ as well as of possible airway complications.²⁸ Finally, limited visibility in the posterior maxilla makes Le Fort I surgery technically demanding, requiring a highly experienced surgeon. The ASO procedure used in our cases limits the surgery to the maxillary anterior segment and thus results in better facial esthetics. An incision is made only in the buccal area, preventing the reduced vascularity and bone necrosis that may occur with Le Fort I surgery. Only local anesthesia is required for insertion of the self-drilling screws.

In maxillary premolar extraction cases, the maxillary intercanine width usually needs to be

expanded for posterior arch coordination during presurgical orthodontic treatment. In the cases shown here, however, the premolars had been extracted during adolescence, and the spaces between the premolars and first molars were closed by the ASO. Therefore, it was less difficult to coordinate the arches after retraction of the anterior segments.

Distalization of the entire maxillary arch using miniscrew anchorage is another option, but only if 3mm or less of movement is needed on each side. Additional miniscrews or a miniplate in the zygomatic buttress would be required to achieve more distalization.²⁹ Distal movement of the entire dentition using miniscrew anchorage is commonly performed in two separate steps: molar distalization followed by anterior retraction. The prolonged treatment time can lead to complications such as root resorption, loss of alveolar bone, and root exposure. In our technique, the palatal miniscrew bonded to the premolars is the primary anchorage device; supplemental maxillary buccal screws are used only to shorten treatment and guide tooth movement.

Conclusion

The alternative treatment approach presented in this article may be considered in borderline cases of Class III relapse where neither orthodontic nor surgical treatment alone will be effective because of continued mandibular growth. The combination of upper ASO and lower BSSRO with miniscrew anchorage avoids the need for more invasive surgery, prosthetic reconstruction, or additional extractions.

ACKNOWLEDGMENTS: This study was partly funded by the Catholic University of Korea, the alumni fund of the Department of Dentistry, and the Graduate School of Clinical Dental Science. The authors thank Drs. Je-Uk Park and Sung-Seo Mo for their valuable suggestions and advice.

REFERENCES

1. Irie, M. and Nakamura, S.: Orthopedic approach to severe skeletal Class III malocclusion, *Am. J. Orthod.* 67:377-392, 1975.
2. Takada, K.; Petdachai, S.; and Sakuda, M.: Changes in dentofacial morphology in skeletal Class III children treated by a modified maxillary protraction headgear and a chin cup: A longitudinal cephalometric appraisal, *Eur. J. Orthod.* 15:211-221, 1993.
3. Tollaro, I.; Baccetti, T.; and Franchi, L.: Craniofacial changes induced by early functional treatment of Class III malocclusion, *Am. J. Orthod.* 109:310-318, 1996.
4. Graber, L.W.: Chin cup therapy for mandibular prognathism, *Am. J. Orthod.* 72:23-41, 1977.
5. Mitani, H. and Fukazawa, H.: Effects of chin cap force on the timing and amount of mandibular growth associated with anterior reversed occlusion (Class III malocclusion) during puberty, *Am. J. Orthod.* 90:454-463, 1986.
6. Sperry, T.P.; Speidel, T.M.; Isaacson, R.J.; and Worms, F.W.: The role of dental compensations in the orthodontic treatment of mandibular prognathism, *Angle Orthod.* 47:293-299, 1977.
7. Proffit, W.R.: Interarch elastics: Their place in modern orthodontics, in *Mechanical and Biological Basics in Orthodontic Therapy*, ed. E. Hösl and A. Baldauf, Hüthig, Heidelberg, Germany, 1991, pp. 173-178.
8. Proffit, W.R.: Retention, in *Contemporary Orthodontics*, ed. W.R. Proffit and H.W. Fields, Mosby, St. Louis, 2000, pp. 599-601.
9. Nanda, R.S. and Nanda, S.K.: Considerations of dentofacial growth in long-term retention and stability: Is active retention needed? *Am. J. Orthod.* 101:297-302, 1992.
10. Mitani, H.; Sato, K.; and Sugawara, J.: Growth of mandibular prognathism after pubertal growth peak, *Am. J. Orthod.* 104:330-336, 1993.
11. Chung, K.; Kim, S.H.; and Kook, Y.: C-orthodontic microimplant for distalization of mandibular dentition in Class III correction, *Angle Orthod.* 75:119-128, 2005.
12. Sugawara, J.; Daimaruya, T.; Umemori, M.; Nagasaka, H.; Takahashi, I.; Kawamura, H.; and Mitani, H.: Distal movement of mandibular molars in adult patients with the skeletal anchorage system, *Am. J. Orthod.* 125:130-138, 2004.
13. Trauner, R. and Obwegeser, H.: The surgical correction of mandibular prognathism and retrognathia with consideration of genioplasty, I. Surgical procedures to correct mandibular prognathism and reshaping of the chin, *Oral Surg. Oral Med. Oral Pathol.* 10:677-689, 1957.
14. Tae, K.C.; Kang, K.W.; Kim, S.C.; and Min, S.K.: Mandibular symphyseal distraction osteogenesis with stepwise osteotomy in adult skeletal class III patient, *Int. J. Oral Maxillofac. Surg.* 35:556-558, 2006.
15. Lee, J.S.; Kim, D.H.; Park, Y.C.; Kyung, S.H.; and Kim, T.K.: The efficient use of midpalatal miniscrew implants, *Angle Orthod.* 74:711-714, 2004.
16. Kyung, S.H.; Hong, S.G.; and Park, Y.C.: Distalization of maxillary molars with a midpalatal miniscrew, *J. Clin. Orthod.* 37:22-26, 2003.
17. Kyung, S.H.; Choi, H.W.; Kim, K.H.; and Park, Y.C.: Bonding orthodontic attachments to miniscrew heads, *J. Clin. Orthod.* 39:348-353, 2005.
18. Bell, W.H. and Condit, C.L.: Surgical-orthodontic correction of adult bimaxillary protrusion, *J. Oral Surg.* 28:578-590, 1970.
19. Lew, K.K.; Loh, F.C.; Yeo, J.F.; and Loh, H.S.: Profile changes following anterior subapical osteotomy in Chinese adults with bimaxillary protrusion, *Int. J. Adult Orthod. Orthog. Surg.* 4:189-196, 1989.
20. Lines, P.A. and Steinhauser, W.W.: Soft tissue changes in relationship to movement of hard structures in orthognathic surgery: A preliminary report, *J. Oral Surg.* 32:891-896, 1974.
21. Kim, J.H.; Joo, J.Y.; Park, Y.W.; Cha, B.K.; and Kim, S.H.: Study of maxillary cortical bone thickness for skeletal anchorage system in Korean, *J. Kor. Assoc. Oral Maxillofac. Surg.* 28:249-255, 2002.
22. Wehrbein, H.; Merz, B.R.; and Diedrich, P.: Palatal bone support for orthodontic implant anchorage—A clinical and radiological study, *Eur. J. Orthod.* 21:65-70, 1999.
23. Block, M.S. and Hoffman, D.R.: A new device for absolute anchorage for orthodontics, *Am. J. Orthod.* 3:251-258, 1995.
24. Wehrbein, H.; Merz, B.R.; Diedrich, P.; and Glatzmaier, J.: The use of palatal implants for orthodontic anchorage: Design and clinical application of the orthosystem, *Clin. Oral Implants Res.* 7:410-416, 1996.
25. Mah, J. and Bergstrand, F.: Temporary anchorage devices: A status report, *J. Clin. Orthod.* 39:132-136, 2005.
26. Cope, J.: Temporary anchorage devices in orthodontics: A paradigm shift, *Semin. Orthod.* 11:3-9, 2005.
27. Hai, H.K. and Egyedi, P.: Preserving the pterygoid plates in cranio-repositioning of the Le Fort I osteotomy, *J. Craniomaxillofac. Surg.* 17:219-221, 1989.
28. Morris, D.E.; Lo, L.J.; and Margulis, A.: Pitfalls in orthognathic surgery: Avoidance and management of complications, *Clin. Plast. Surg.* 34:e17-29, 2007.
29. Sugawara, J.; Kanzaki, R.; Takahashi, I.; Nagasaka, H.; and Nanda, R.: Distal movement of maxillary molars in nongrowing patients with the skeletal anchorage system, *Am. J. Orthod.* 129:723-733, 2006.